



This is a digital copy of a book that was preserved for generations on library shelves before it was carefully scanned by Google as part of a project to make the world's books discoverable online.

It has survived long enough for the copyright to expire and the book to enter the public domain. A public domain book is one that was never subject to copyright or whose legal copyright term has expired. Whether a book is in the public domain may vary country to country. Public domain books are our gateways to the past, representing a wealth of history, culture and knowledge that's often difficult to discover.

Marks, notations and other marginalia present in the original volume will appear in this file - a reminder of this book's long journey from the publisher to a library and finally to you.

Usage guidelines

Google is proud to partner with libraries to digitize public domain materials and make them widely accessible. Public domain books belong to the public and we are merely their custodians. Nevertheless, this work is expensive, so in order to keep providing this resource, we have taken steps to prevent abuse by commercial parties, including placing technical restrictions on automated querying.

We also ask that you:

- + *Make non-commercial use of the files* We designed Google Book Search for use by individuals, and we request that you use these files for personal, non-commercial purposes.
- + *Refrain from automated querying* Do not send automated queries of any sort to Google's system: If you are conducting research on machine translation, optical character recognition or other areas where access to a large amount of text is helpful, please contact us. We encourage the use of public domain materials for these purposes and may be able to help.
- + *Maintain attribution* The Google "watermark" you see on each file is essential for informing people about this project and helping them find additional materials through Google Book Search. Please do not remove it.
- + *Keep it legal* Whatever your use, remember that you are responsible for ensuring that what you are doing is legal. Do not assume that just because we believe a book is in the public domain for users in the United States, that the work is also in the public domain for users in other countries. Whether a book is still in copyright varies from country to country, and we can't offer guidance on whether any specific use of any specific book is allowed. Please do not assume that a book's appearance in Google Book Search means it can be used in any manner anywhere in the world. Copyright infringement liability can be quite severe.

About Google Book Search

Google's mission is to organize the world's information and to make it universally accessible and useful. Google Book Search helps readers discover the world's books while helping authors and publishers reach new audiences. You can search through the full text of this book on the web at <http://books.google.com/>

PLEASE DO NOT REMOVE THIS BAND

LANE MEDICAL LIBRARY STANFORD



2 45 0422 2631

REMOTE STORAGE

Please return at the circulation desk.
To renew your material call:
(650) 723-6691 ext. 3

Date due in Lane Library:


OSTEOLOG

A

ATLAS

E 101
138
1866
ATLAS


955



LIBRARY

Ward

MEDICAL LIBRARY





OSTEOLOGY:

A CONCISE

DESCRIPTION OF THE HUMAN SKELETON,

ADAPTED FOR

THE USE OF STUDENTS IN MEDICINE,

BY

ARTHUR TREHERN NORTON,

ASSISTANT LECTURER ON, AND DEMONSTRATOR OF, ANATOMY, ST. MARY'S MEDICAL SCHOOL.

Atlas of Plates.

LONDON:

ROBERT HARDWICKE, 192, PICCADILLY.

1866.

11
8
6
125

PLATE XI.

THE FOOT.

- | | |
|--|---|
| 1. Os calcis. | 8. Ligamentous surface. |
| 2. External tubercle. O. abductor minimi digiti. | 9. Scaphoid. |
| 3. Calcaneo astragaloid groove for the interosseous ligament of same name. | 10. Internal cuneiform. |
| 4. O. Extensor brevis digitorum, from the upper and outer surface of the anterior extremity of the os calcis. | 11. Middle cuneiform. |
| 5. Astragalus. | 12. External cuneiform. |
| 6. Surface for articulation with the inferior surface of the lower extremity of the tibia. | 13. Cuboid. |
| 7. Surface for articulation with the outer malleolus. | 14. Groove for the tendon of the peroneus longus. |
| | 15. Tuberosity of the fifth metatarsal bone into which is inserted the peroneus brevis. |
| | 16. I. Peroneus tertius. |

The interosseous muscles arise from the adjacent surfaces of all the metatarsal bones.

PLATE XII.

OCCIPITAL BONE.

1. Internal spine: the point of union of the four ossific points and meeting of the sinuses or torcular Herophili.
2. Longitudinal sinus, the borders of which attach the falx major.
3. Lateral sinus, borders of which attach the tentorium cerebelli.
4. Occipital sinus, borders of which attach the falx cerebelli.
5. Foramen magnum: transmits spinal cord, its membranes and vessels out of the skull, the spinal accessory nerves and vertebral arteries into the skull.
6. Anterior condyloid foramen, through which the ninth nerve leaves the skull.
7. Jugular process. **I.** rectus capitis lateralis.
8. Continuation of the lateral sinus.
9. Jugular fossa, or part of the foramen lacerum posterius.
10. Basilar process.
11. Groove for medulla oblongata and pons Varolii.
12. External spine, attaches ligamentum nuchæ.
13. Superior curved line of the occiput and
14. **O.** Trapezius internally,
15. Occipito frontalis in the centre and
16. **I.** Sterno mastoid externally.
17. Inferior curved line of the occiput,
18. **I.** Rectus capitis posticus minor internally,
19. **I.** Rectus capitis posticus major in the centre,
20. **I.** Obliquus superior externally.
21. **I.** Complexus between the two curved lines.
22. **I.** Splenius capitis between the two curved lines.
23. Condyle.

24. Posterior condyloid foramen, transmits a small vein inwards to lateral sinus.
25. Attachment of odontoid ligament
26. Spine of the basilar process and superior constrictor of pharynx.
27. **I.** Rectus capitis anticus major: minor into fossa at the side of spine.
- 28 to 29. Articulates with the parietal bone and forms the lambdoid suture.
- 29 to 30. Articulates with the mastoid portion of the temporal bone.
31. Union with the body of the sphenoid bone.

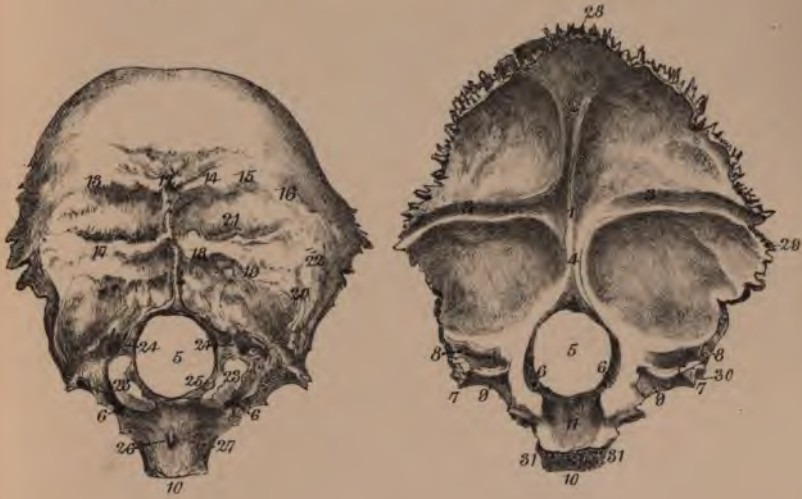PARIETAL BONE.

1. Grooves for the middle meningeal branches of artery.
2. Half-groove along superior border for superior longitudinal sinus.
3. Fossæ for Pacchionian bodies.
4. Groove on posterior inferior angle for the lateral sinus.
5. Parietal protuberance, the commencing point of ossification.
6. Temporal ridge, the attachment of the temporal aponeurosis.
7. **O.** Temporal muscle from temporal fossa.
8. Superior border, articulates with fellow of opposite side to form the sagittal suture.
9. Anterior border, articulates with frontal bone to form coronal suture.
10. Posterior border, articulates with occipital bone to form the lambdoid suture.
11. Inferior border, articulates from above to the mastoid portion of the temporal bone, the remainder with the squamous portion of the temporal bone, except a small portion at the anterior inferior angle, which articulates with the great wing of the sphenoid bone.

THE OCCIPITAL BONE.

EXTERNAL VIEW.

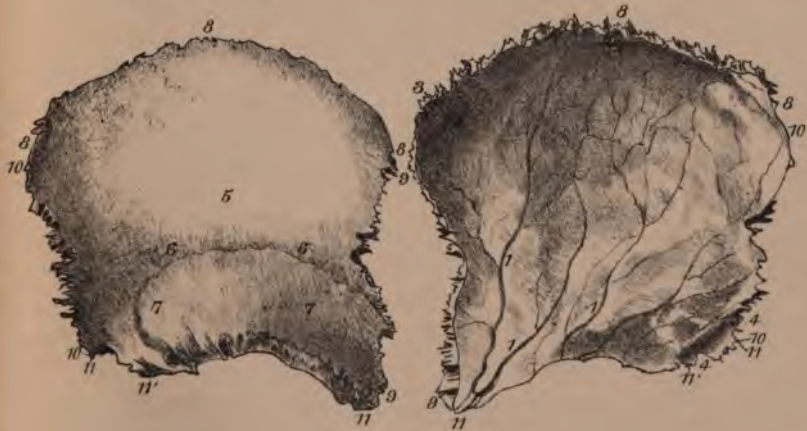CEREBRAL VIEW.



THE PARIETAL BONE.

EXTERNAL VIEW.

CEREBRAL VIEW.







THE TEMPORAL BONE

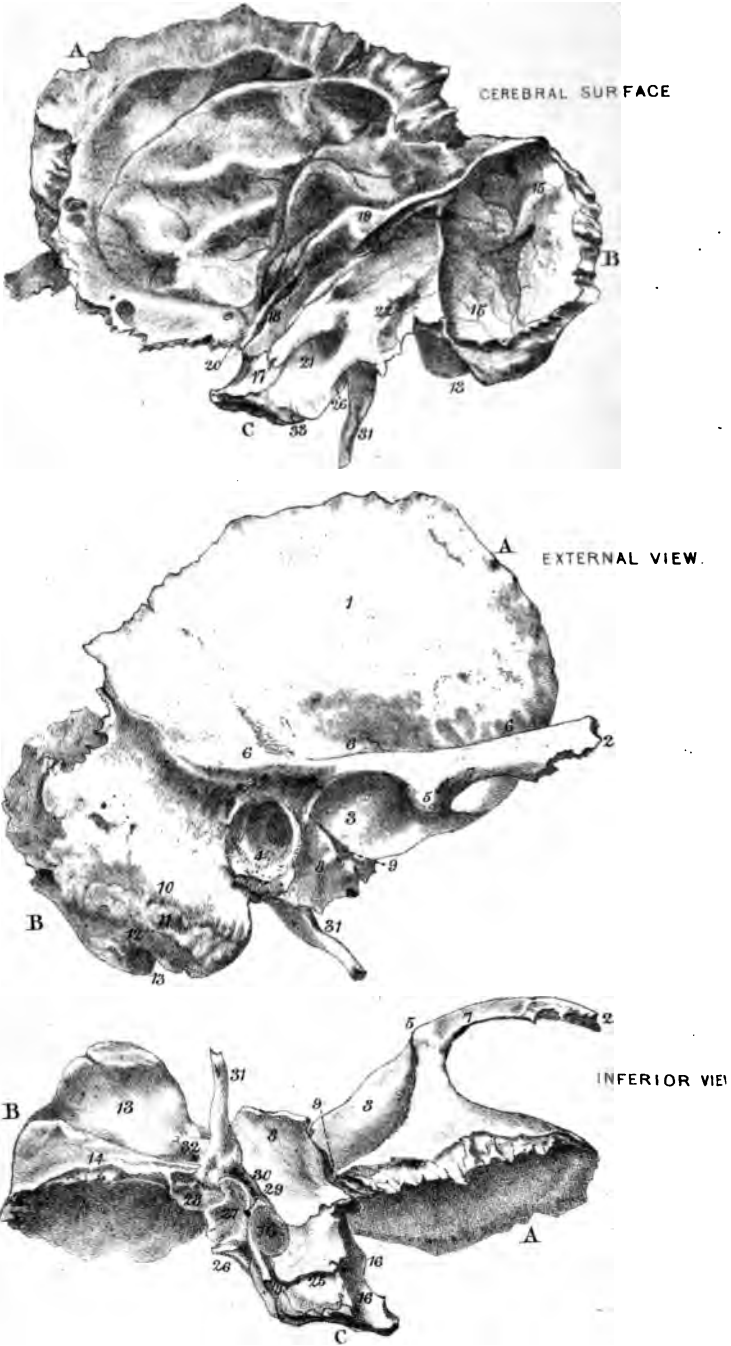


PLATE XIII.

THE TEMPORAL BONE.

- A. Squamous portion.
- B. Mastoid portion.
- C. Petrous portion.
1. **O.** Temporal muscle from the temporal fossa.
 2. Zygomatic process.
 3. Condylloid fossa or glenoid cavity.
 4. External auditory meatus.
 5. Tubercle upon zygomatic process for attachment of the external lateral ligament of the temporo maxillary joint.
 6. Line attaching the temporal aponeurosis.
 7. **O.** Masseter muscle from lower margin of the zygoma.
 8. Vaginal or auditory process.
 9. Glasserian fissure, transmits chorda tympani nerve, small tympanic vessels, laxator tympani muscle and contains the processus gracilis of the malleus.
 10. **I.** Sterno mastoid into outer surface of mastoid portion of the temporal bone.
 11. **I.** Splenius capitis immediately below the sterno mastoid.
 12. **I.** Trachelo mastoid below splenius.
 13. Digastric fossa. **O.** posterior belly of the digastric muscle.
 14. Groove for the occipital artery.
 15. Groove for the lateral sinus.
 16. Carotid canal, transmits the carotid artery and filaments of the sympathetic nerve.
 17. Depression for Gasserian ganglion of the fifth nerve.
 18. Groove leading to hiatus Fallopii and occupied by the Vidian nerve.
 19. Elevation due to the superior semicircular canal.
 20. Two canals not seen in the diagram: the upper transmits the tensor tympani muscle, the lower is the Eustachian tube.
 21. Meatus auditorius internus into which the seventh nerve enters.
 22. Aqueductus vestibuli, transmits a small vein.
 23. Small depression attaching the dura mater.
 24. Groove for superior petrosal sinus, running along the upper margin of the petrous portion outwards to the lateral sinus.
 25. Square surface giving origin to levator palati and tensor tympani.
 26. Aqueductus cochleæ.
 27. Jugula fossa, assists in forming the foramen lacerum posterius.
 28. Surface for articulation with the jugular process of the occipital bone.
 29. Foramen for Jacobson's nerve.
 30. Foramen for Arnold's nerve.
 31. Styloid process, it gives origin to stylo pharyngeus, stylo hyoid, and stylo glossus muscles from above downwards, and to the stylo maxillary and stylo hyoid ligaments, the latter by its apex.
 32. Stylo mastoid foramen, it transmits the portio dura or facial division of the seventh nerve out of the skull, and is entered by a small stylo mastoid artery.
 33. Inferior petrosal sinus, formed by the junction of the basilar process of the occipital and the petrous portion of the temporal, and running downwards to the jugular foramen or foramen lacerum posterius.

PLATE XIV.

FRONTAL BONE.

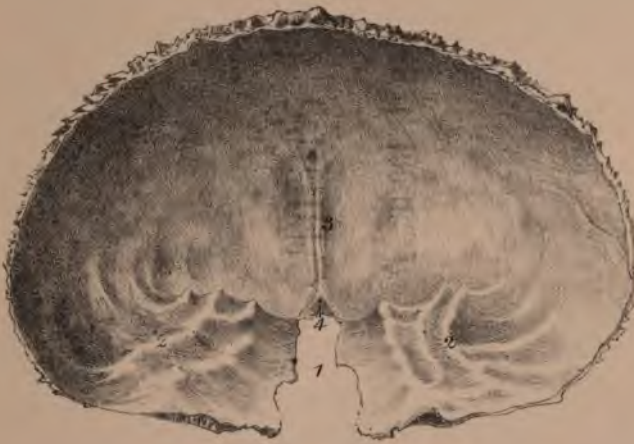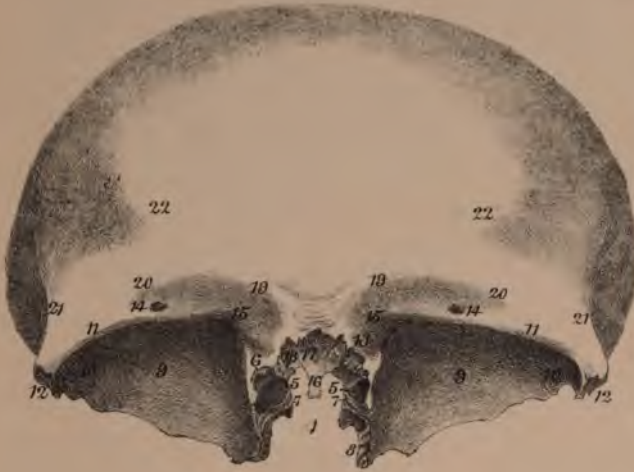1. Ethmoid space occupied by the ethmoid bone.
2. Anterior cranial fossa.
3. Frontal crest, attaches the falx major, and dividing above into two borders encloses the superior longitudinal sinus.
4. Foramen cæcum, often a small canal transmitting a vein from the nose.
5. Cells completed by the ethmoid bone.
6. Frontal sinus, a space between the tables of the frontal bone, communicating with the middle meatus of the nose.
7. Anterior ethmoidal groove, transmits the naso lobular nerve of the ophthalmic and a small artery.
8. Posterior ethmoid groove, transmits an anterior meningeal artery from the ophthalmic.
9. Roof of the orbit.
10. Lachrymal fossa for lachrymal gland.
11. Superior orbital ridge.
12. External angular process, articulates with the malar bone.
13. Internal angular process, articulates with the lachrymal bone.
14. Supra orbital foramen, transmits supra orbital nerve and artery from ophthalmic.
15. Depression in which is attached the pulley for the tendon of the superior oblique muscle of the eye.
16. Nasal spine of the frontal bone: it articulates with the two nasal bones in front and with the perpendicular plate of the ethmoid behind.
17. Point of articulation with the nasal bones.
18. Point of articulation with the nasal process of the superior maxilla.
19. Elevation due to the frontal sinus.
20. Supraciliary ridge, giving origin at its internal part to the corrugator supercilii muscle.
21. Temporal ridge, extending from the external angular process upwards and backwards: it attaches the temporal aponeurosis.
22. Frontal eminence, the commencing point of ossification.

ETHMOID BONE.

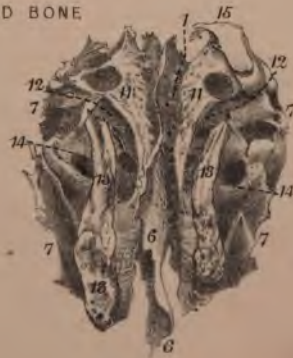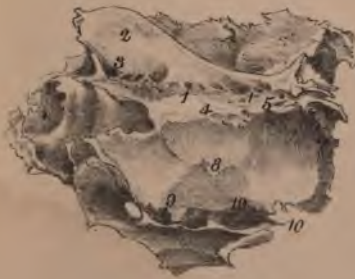1. Cribriform plate, through which the olfactory nerve-filaments leave the skull.
2. Crista galli, attaches falx major.
3. Nasal fissure, transmits naso lobular nerve from the skull into the nose.
4. Anterior ethmoidal groove, transmits naso lobular nerve and small artery from the orbit into the skull.
5. Posterior ethmoidal groove, transmits a small anterior meningeal branch of artery from the orbit into the skull.
6. Vertical plate of the ethmoid.
7. Lateral mass, composed of large ethmoidal cells.
8. Os planum, or orbital plate of the ethmoid bone.
9. Half cells below the os planum, completed by the superior maxilla.
10. Point of articulation with the palate bone.
11. Superior turbinated bone.
12. Superior meatus, into which are seen opening the orifices of the posterior ethmoidal cells. The sphenoidal cells sometimes join the posterior ethmoidal cells and open with them.
13. Middle turbinated bone.
14. Middle meatus: it receives the anterior ethmoidal cells, one of which is joined by the duct from the frontal sinus, and produces a funnel-shaped duct, the infundibulum.
15. A portion of the sphenoidal turbinated bone adherent to the ethmoid.

THE FRONTAL BONE

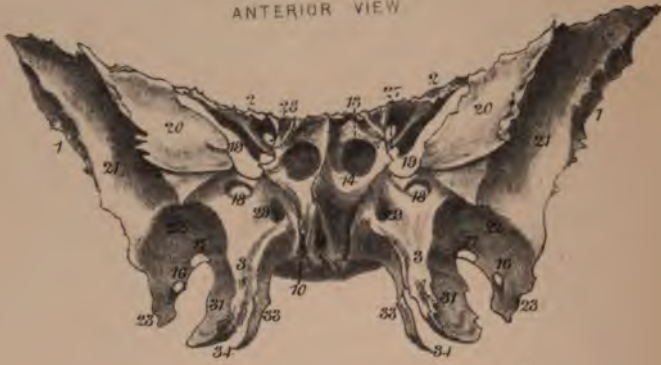
Plate XIV



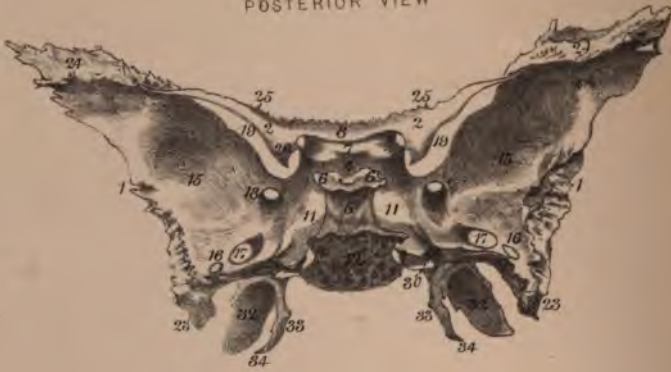THE ETHMOID BONE



THE SPHENOID BONE
ANTERIOR VIEW

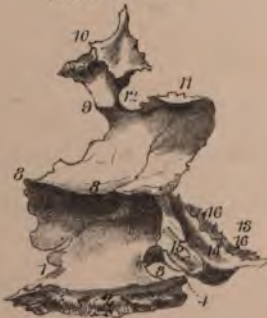

POSTERIOR VIEW



THE PALATE BONE

INTERNAL VIEW



INFERTIOR VIEW

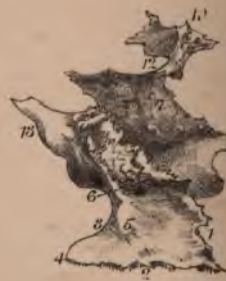

PLATE XV.

SPHENOID BONE.

1. Great wing.
2. Lesser wing, attached by two roots.
3. Pterygoid process.
4. Pituitary fossa, receives the pituitary gland or body.
5. Dorsum Ehippii.
6. Posterior clinoid processes, attach the tentorium cerebelli.
7. Olivary process upon which the optic commissure lies.
8. A portion of the superior surface of the body in front of the olivary process.
9. Rostrum, articulates with ala of the vomer.
10. Pterygo palatine canal, transmits pterygo palatine vessels and nerve.
11. Groove in which lie the cavernous sinus and the internal carotid artery.
12. Posterior surface, articulates with the basilar process of the occiput.
13. Sphenoid cells.
14. Sphenoidal turbinated bone.
15. Cerebral surface of great wing.
16. Foramen spinosum, transmits middle meningeal artery into skull.
17. Foramen ovale, transmits inferior maxillary nerve, or third division of fifth, out of the skull, and a small artery, the meningeal parva, into the skull.
18. Foramen rotundum, through which the superior maxillary nerve, or second division of fifth, leaves the skull.
19. Foramen lacerum anterius or sphenoidal fissure, through which the third, fourth, ophthalmic (first division of fifth) and sixth nerves, pass from the skull into the orbit, and the ophthalmic vein returns.
20. Orbital surface of great wing, quadrilateral in form, contributes to outer wall of orbit.
21. External surface of great wing, its upper portion belongs to temporal fossa and gives origin to temporal muscle.
22. External surface of great wing, its lower portion, belongs to zygomatic fossa, and gives origin to the external pterygoid muscle.
23. Spine of the sphenoid, attaches internal lateral ligament of lower jaw and O. laxator tympani muscle.
24. Triangular surface for articulation with the frontal bone.
25. Line of articulation of the lesser wing with the ethmoid bone.
26. Anterior clinoid process, attaches tentorium cerebelli.
27. Lower root of lesser wing.

28. Optic foramen, transmits the optic nerve and ophthalmic artery. Around the front of this foramen the muscles of the eye arise.
29. Anterior orifice of Vidian canal, transmits Vidian nerve and artery.
30. Posterior orifice of Vidian canal.
31. External surface of external pterygoid plate and O, external pterygoid muscle.
32. Internal surface of external pterygoid plate and O, internal pterygoid muscle.
33. Internal pterygoid plate, at the base of which an elliptical depression, the scaphoid fossa, gives origin to the tensor palati muscle.
34. Hamular process, around which the tensor palati muscle turns.

PALATE BONE.

1. Anterior border of horizontal plate, articulates with the palatine process of superior maxilla.
2. Internal border, articulates with fellow.
3. Posterior border.
4. Posterior nasal spine.
5. Transverse ridge. I. tensor palati.
6. Posterior palatine canals, transmit posterior palatine vessels and nerves.
7. External surface of vertical plate of the palate bone, articulates with superior maxilla.
8. Inferior turbinated ridge for inferior spongy bone.
9. Middle turbinated ridge for middle spongy bone.
10. Orbital process, presents five surfaces: anterior articulates with superior maxilla; posterior articulates with sphenoidal turbinated; internal articulates with ethmoid; superior contributes to orbital fossa; external contributes to sphenomaxillary fossa.
11. Sphenoidal process presents three surfaces: superior articulates with body of the sphenoid; inferior contributes to nares; external contributes in part to the sphenomaxillary fossa, and in part overlaps the internal pterygoid plate.
12. Sphenopalatine notch or foramen transmits sphenopalatine vessels and nerves into the nose.
13. Tuberosity of the palate bone.
14. Groove contributing to pterygoid fossa.
15. Groove for internal pterygoid plate.
16. Rough margin for external pterygoid plate.

PLATE XVI.

SUPERIOR MAXILLA.

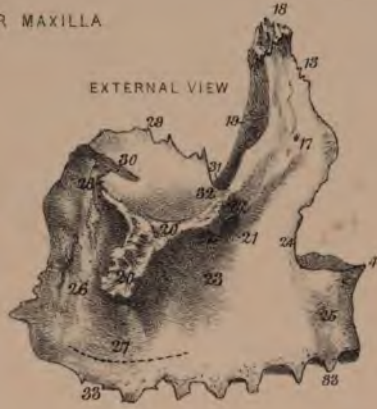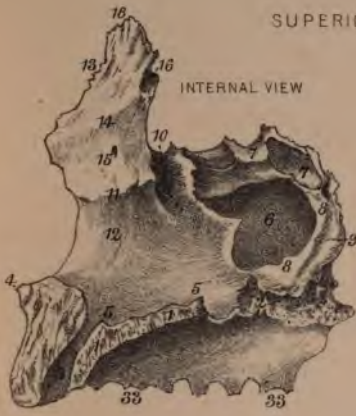1. Palatine process, articulates with fellow by its internal border and with horizontal plate of palate bone by its posterior border.
2. Space completed by horizontal plate of the palate bone.
3. Naso palatine canal, transmits naso palatine vessels and nerve.
4. Anterior nasal spine.
5. Crest for the reception of the vomer.
6. Antrum of Highmore.
7. Half cells completed by palate and ethmoid bones.
8. Surface for articulation with perpendicular plate of the palate bone.
9. Groove completed as a canal by palate bone for posterior palatine vessels and nerves.
10. Groove for lachrymal canal.
11. Turbinated crest, articulates with inferior spongy bone.
12. Outer wall of inferior meatus.
13. Nasal process of the superior maxilla.
14. Crest for articulation with middle spongy bone.
15. Outer wall of middle meatus.
16. Cell completed by ethmoid bone.
17. External surface of the nasal process and *O. levator labii superioris aequalis nasi*.
18. Apex of nasal process, articulates with frontal bone.
19. Posterior internal border, articulates with lachrymal bone.
20. Articulation with malar bone.
21. Infra orbital foramen, transmits infra orbital vessels and nerve, branches of the superior maxillary nerve and internal maxillary artery.
22. *O. Levator labii superioris*, from the surface above the infra orbital foramen.
23. Canine fossa. *O. levator anguli oris*.
24. *O. Compressor naris*.
25. Myrtiliform fossa and *O. depressor alae nasi*.
26. Zygomatic surface.
27. *O. Buccinator* muscle, from outer surface of alveolar border, as far forward as the three molar teeth.
28. Margin of the orbital plate which bounds the sphenomaxillary fissure.
29. Internal margin of the orbital plate, articulates with the ethmoid—lachrymal in front, os planum of ethmoid, and at the posterior angle with the orbital process of the palate bone.
30. Infra orbital canal traversing the orbital surface.
31. The orbital orifice of the lachrymal canal.

32. *O. Inferior oblique* muscle of the eye, from the inner angle of the floor of the orbit.
33. Alveolar border, with spaces for the roots of eight teeth.

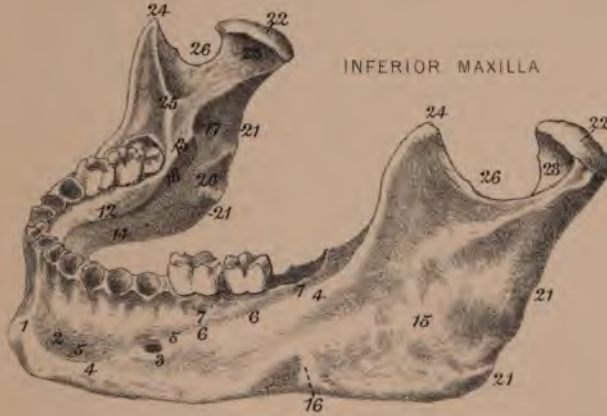
INFERIOR MAXILLA.

1. Symphysis of lower jaw.
2. Mental fossa. *O. levator menti*.
3. Mental foramen, transmits mental nerve and artery, branches of the inferior dental.
4. External oblique line, below which *I. platymyoides*.
5. *O. Depressor labii inferioris*.
6. *O. Depressor anguli oris*.
7. *O. Buccinator*, as far forward as the three molar teeth.
8. Symphysis (internal view).
9. Tubercular elevation, sometimes presenting four tubercles, of which the upper two give origin to the two geniohyoglossus muscles and the lower to the two geniohyoid.
10. Depression for *O. anterior belly of the digastric*.
11. Sublingual fossa, the position of the sublingual gland.
12. Internal oblique line, or mylohyoid ridge. *O. mylohyoid* muscle.
13. *O. Superior constrictor of pharynx*, from the posterior part of the mylohyoid ridge.
14. Submaxillary fossa, position of the submaxillary gland.
15. *I. Masseter* upon the outer surface of the ramus.
16. Groove for the facial artery situated at the anterior border of the masseter muscle.
17. Inferior dental canal, transmits inferior dental vessels and nerve to the teeth.
18. Mylohyoid groove traversed by the mylohyoid vessels and nerve.
19. Vaginal process, attaches internal lateral ligament of lower jaw.
20. *I. Pterygoideus internus* into inner surface of the ramus.
21. Attachment of the stylo maxillary ligament into the posterior margin and angle of the ramus.
22. Condyle of the lower jaw.
23. *I. Pterygoideus externus* into depression in front of the neck of the condyle.
24. Coronoid process.
25. *I. Temporal* muscle into inner surface of coronoid process.
26. Sigmoid notch through which the masseteric vessels and nerve pass outwards to the muscle.

SUPERIOR MAXILLA



INFERIOR MAXILLA



SECTION OF INFERIOR MAXILLA
INTERNAL VIEW

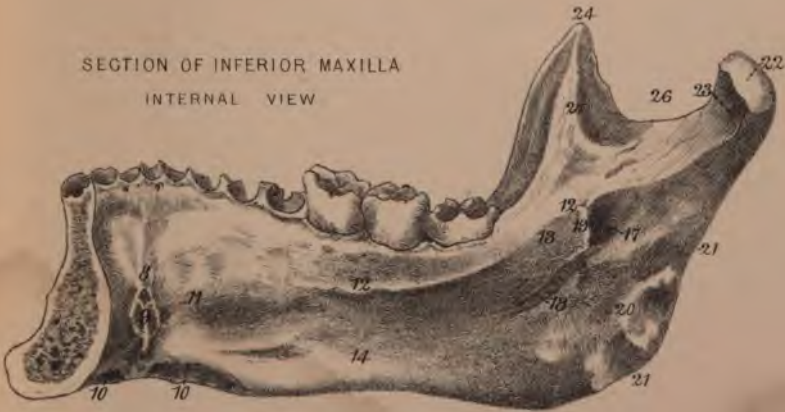

PLATE XVII.

MALAR BONE.

1. External surface.
2. **I.** Some fibres of the orbicularis palpebrarum, but a large portion of the muscle extends some distance over the external surface.
3. **O.** Zygomaticus major and zygomaticus minor, the latter being superior in position when present.
4. Part of the internal aspect above the zygomatic process, contributing to the temporal fossa and **O**, temporal muscle.
5. Part contributing to the zygomatic fossa.
6. Rough surface for articulation with the malar process of the superior maxilla.
7. Orbital border from which the orbital plate extends backwards to form part of the floor and outer wall of the orbit.
- 8 to 9. Margin which articulates with the frontal bone.
- 9 to 10. Articulates with the orbital plate of the sphenoid bone.
- 10 to 11. Articulates with the orbital plate of the superior maxillary bone.
12. Inferior or zygomatic border.
13. **O**, Some anterior fibres of the masseter muscle.
14. Posterior or temporal border, of which the upper part attaches the temporal aponeurosis, and the lower rough part articulates with zygomatic process of the temporal bone.
15. Anterior or maxillary border articulates with the superior maxillary bone.

NASAL BONE.

1. Anterior or external surface covered by the pyramidalis nasi.
2. Posterior surface contributes to the roof of the nose.
3. Superior border, articulates with the rough notch in the frontal bone.
4. Inferior border, connected with the lateral cartilage of the nose.
5. Internal or anterior border very thick above, articulates with its fellow.
6. External or posterior border, articulates with the anterior border of the nasal process of the superior maxillary bone.

LACHRYMAL BONE.

1. Anterior portion of the external surface, is in the form of a groove, and assists in forming the lachrymal canal.

2. Posterior portion of the external surface contributes to the inner wall of the orbit.
3. Anterior portion of internal surface contributes to the middle meatus of the nose.
4. Posterior portion of internal surface overlaps the ethmoid bone.
- 5 to 6. Superior border, articulates with frontal bone.
- 6 to 7. Anterior border, articulates with the nasal process of the superior maxillary bone.
- 7 to 8. Inferior border, articulates with the inferior turbinated in front and behind with the orbital plate of the superior maxilla.
- 5 to 8. Posterior border, articulates with the os planum of the ethmoid.

VOMER.

1. Groove for the naso palatine nerve.
- 2 to 3. Superior border and expanding ala, which embrace the rostrum of the sphenoid bone.
- 4 to 5. Inferior border: it is received into a groove formed by the union of the two palatine processes of the superior maxilla, and the two horizontal plates of the sphenoid bone.
- 3 to 4. Posterior border, the separation of the two posterior nares.
- 2 to 5. Anterior border, articulates with the perpendicular plate of the ethmoid.

INFERIOR TURBINATED, OR SPONGY BONE.

1. Internal surface.
 2. Anterior extremity, rounded.
 3. Posterior extremity, pointed.
 - 2 to 4. The superior border, articulates with the inferior crest of the superior maxilla.
 4. An ascending process, articulates with the lachrymal bone, and immediately behind this it is in contact with the lateral mass of the ethmoid bone.
 - 5 to 6. From this part a lamina curves over, outwards and downwards, to assist in forming the inner wall of the antrum of Highmore.
 - 6 to 3. Articulates with the lower ridge upon the perpendicular plate of the palate bone.
- The inferior margin of the inferior spongy bone is free within the nose.

PLATE XVIII.

THE BASE OF THE SKULL.

INFERIOR VIEW.

1. Roof of the mouth.
2. Anterior palatine canal, transmits same vessels and nerve.
3. Posterior palatine foramen, transmits same vessels and nerves.
4. Posterior orifice of the nares.
5. Internal pterygoid plate with the hamular process curving from its apex.
6. External pterygoid plate. *O.* external and internal pterygoid muscles.
7. Foramen ovale, transmits arteria meningea parva into the skull, third division of fifth nerve out of skull.
8. Foramen spinosum (arteria meningea media into the skull).
9. Spine of sphenoid, attaches internal lateral ligament of lower jaw and *O.* laxator tympani muscle.
10. Basilar process. *I.* superior constrictor of pharynx into a central tubercle, and rectus capitis anticus major and minor upon each side.
11. Foramen lacerum medium.
12. *O.* Levator palati and tensor tympani, from square surface upon under surface of the petrous portion of temporal bone.
13. Carotid canal for carotid artery.
14. Foramen lacerum posterius, transmits the jugular vein and the three trunks of the eighth nerve.
15. Aqueductus cochleæ.
16. Foramen for Jacobson's nerve.
17. Vaginal process.
18. Stylo mastoid foramen, transmits the portio dura of the seventh nerve and a stylo mastoid artery.
19. Digastric fossa. *O.* posterior belly of digastric.
20. Glasserian fissure, transmits chorda tympani nerve, laxator tympani muscle, tympanic artery, and contains the processus gracilis of the malleus.
21. Glenoid cavity—anterior part for temporo maxillary articulation, posterior part occupied by a process of the parotid gland.
22. Foramen magnum (spinal cord and its membranes and vessels out of skull, vertebral arteries and spinal accessory nerves into skull).
23. Condyle of the occiput.
24. Anterior condyloid foramen, transmits ninth nerve.
25. Posterior condyloid foramen, transmits a small vein inwards to lateral sinus.
26. Jugular process. *I.* rectus capitis lateralis.
27. Inferior curved line. *I.* rectus capitis posterior minor internally, major in the centre, and superior oblique externally.
28. Superior curved line. *O.* trapezius internally, occipito frontalis in the centre, and *I.* sterno mastoid externally.
29. *I.* Complexus between the two curved lines.
30. *I.* Spleneus capitis between the two curved lines external to the complexus.

CEREBRAL VIEW

(Three Fossæ).

ANTERIOR FOSSA.

1. Crista galli, attaches falx major.
2. Foramen cæcum.
3. Cribriform plate, perforated for the filaments of the olfactory nerve.
4. Nasal fissure for naso lobular nerve.
5. Ethmoid foramina—anterior transmits the naso lobular nerve from the orbit into the skull; posterior a small anterior meningeal artery.
6. Anterior clinoid process, attaches tentorium cerebelli.

MIDDLE FOSSA.

7. Pituitary fossa.
8. Dorsum Ephippii, the superior angles of which are termed the posterior clinoid processes, and attach the tentorium cerebelli.
9. Olfactory process grooved above by the optic commissure.
10. Groove for cavernous sinus and for the internal carotid artery.
11. Foramen lacerum anterius or sphenoidal fissure, transmits the third fourth, first division of fifth, and the sixth nerve into the orbit, and the ophthalmic vein back into the skull.
12. Foramen rotundum, transmits the second division of the fifth nerve.
13. Foramen ovale (third division of fifth nerve and small meningeal artery).
14. Foramen spinosum, transmits the middle meningeal artery into skull.
15. Foramen lacerum medium, occupied by a fibro cartilage.
16. Groove upon the anterior surface of the petrous portion of the temporal bone, traversed by the Vidian nerve, and enters the bone at the hiatus Fallopii.
17. Fossa for Gasserian ganglion.
18. Prominence of the superior semicircular canal.

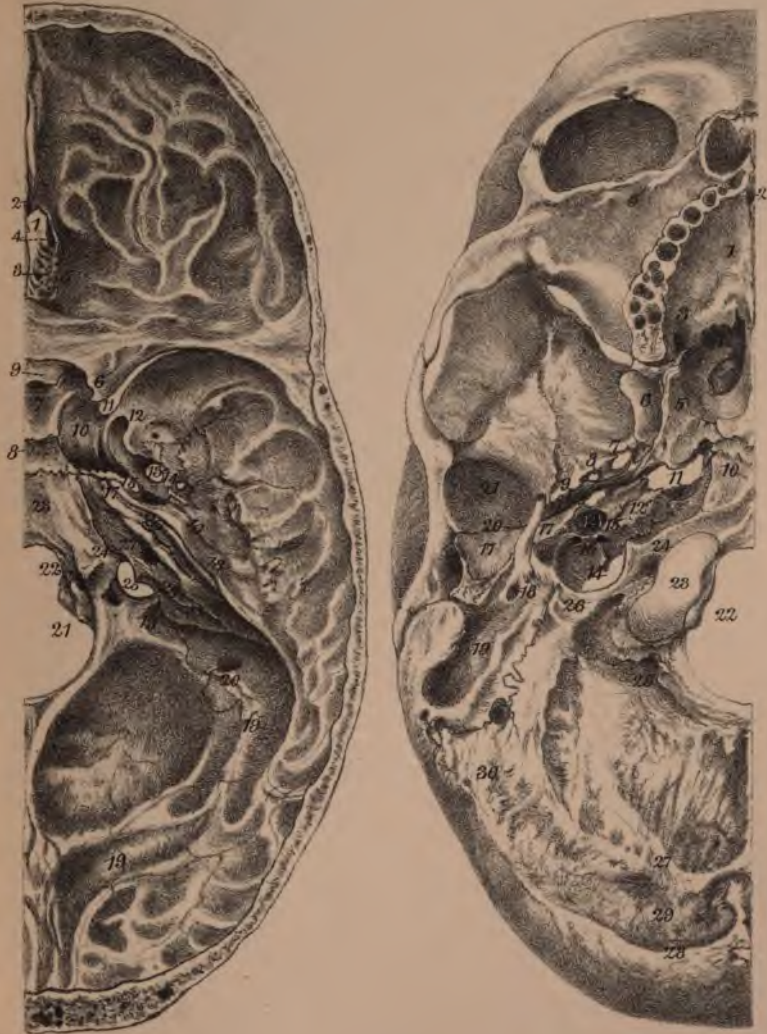
POSTERIOR FOSSA.

19. Groove for lateral sinus—borders attach tentorium cerebelli.
20. Mastoid foramen—vein entering lateral sinus.
21. Foramen magnum.
22. Anterior condyloid foramen (hypoglossal or ninth nerve).
23. Basilar process grooved for medulla.
24. Groove for inferior petrosal sinus.
25. Foramen lacerum posterius or jugular foramen.
26. Groove for superior petrosal sinus.
27. Meatus auditorius internus, transmits the portio mollis and portio dura of the seventh nerve.
28. Aqueductus vestibuli, transmits a small vein.

THE BASE OF THE SKULL

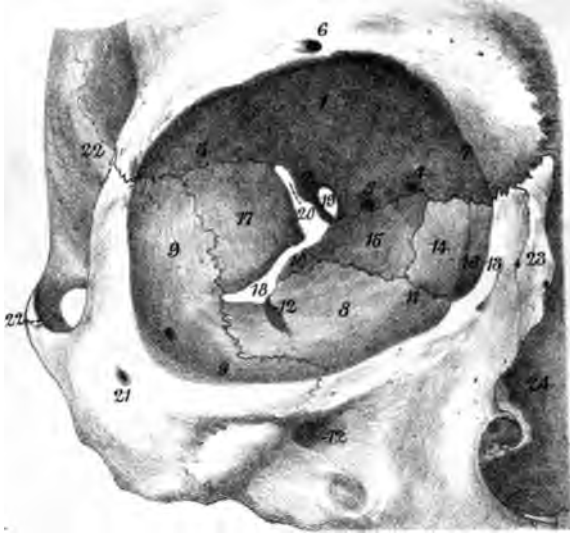
CEREBRAL VIEW.

INFERIOR VIEW.





THE ORBITAL FOSSA



THE NASAL FOSSA

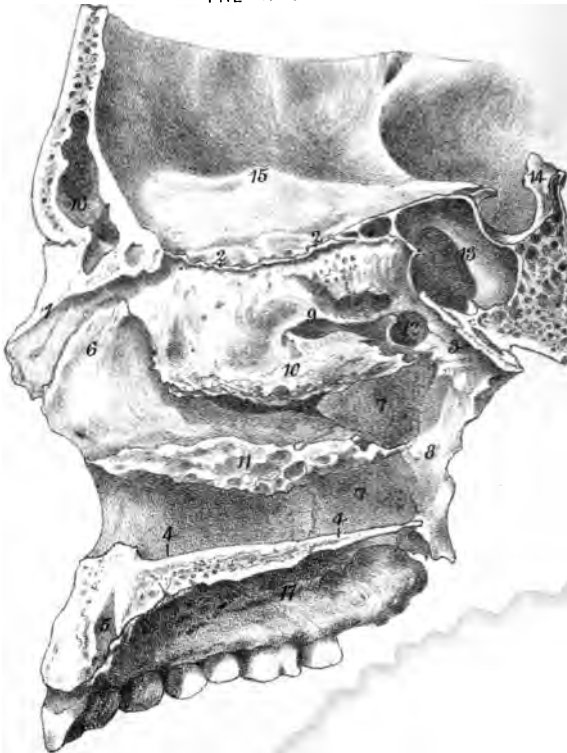


PLATE XIX.

ORBITAL FOSSA.

1. Orbital plate of the frontal bone, forming the chief part of the roof of the orbit.
2. Lesser wing of the sphenoid bone.
3. Fossa in the outer angle of the roof of the orbit for the lachrymal gland.
4. Anterior ethmoidal foramen, transmits naso lobular branch of ophthalmic nerve.
5. Posterior ethmoidal foramen, transmits an anterior meningeal artery from ophthalmic.
6. Supra orbital foramen, transmits supra orbital nerve and artery from the orbit to the forehead.
7. Depression in which is attached the cartilaginous pulley for the superior oblique muscle of the eye.
8. Orbital plate of the superior maxilla, forms the chief part of the floor of the orbit.
9. Orbital plate of the malar bone, contributes to the outer wall and to the floor.
10. Orbital process of the palate bone, contributes slightly to the floor.
11. O. Inferior oblique from the superior maxilla close to the canal for the lachrymal sac.
12. Infra orbital canal, transmits infra orbital nerve from superior maxillary nerve and infra orbital artery from internal maxillary.
13. Nasal process of the superior maxilla.
14. Lachrymal bone, inner wall of orbit.
15. Orbital plate of the ethmoid, contributes to inner wall.
16. Lachrymal canal.
17. Orbital plate of sphenoid, forms the chief part of the outer wall.
18. Spheno maxillary fissure connecting the orbit with the zygomatic and spheno maxillary fossæ.
19. Optic foramen, transmits optic nerve and ophthalmic artery into orbit: around it the muscles of the eye arise.
20. Foramen lacerum anterius or sphenoidal fissure, transmits third, fourth, first division of fifth, and the sixth nerves into the orbit, and the ophthalmic vein, into the skull.
21. Malar bone.
22. Zygomatic process, above which is the temporal fossa and origin of the temporal muscle.
23. Nasal bone.
24. Cavity of the nose.

NASAL FOSSA.

1. Nasal bone.
2. Cribriform plate of ethmoid through which the filaments of the olfactory nerve pass into the nose.
3. Lower surface of the body of the sphenoid, with the ala of the vomer and sphenoidal process of the palate bone uniting.
4. Floor of the nose formed by the palatine process of the superior maxilla, and the horizontal plate of the palate bone.
5. Naso palatine canal, transmits the naso palatine or anterior palatine nerve and vessels.

The internal wall of the nose is not seen in the plate. It is composed of the elevated internal margin of the palatine process of the superior maxilla, and of the horizontal plate of the palate bone; the perpendicular plate of the ethmoid bone; and the spine of the frontal bone. The external wall of the nose is formed by—
6. Nasal process of the superior maxilla;
Nasal surface of lachrymal bone; Cellular mass of ethmoid; } not seen, being hidden by the turbinated bone.
7. Perpendicular plate of palate bone.
8. Internal pterygoid plate. Connected with the outer wall are the turbinated bones overlapping the meatus or sinus of the nose.
9. Superior spongy or turbinated bone, overlapping the superior meatus, into which the posterior ethmoidal cells open, and from the outer side the spheno palatine foramen.
10. Middle turbinated bone, overlapping the middle meatus, into which open the anterior ethmoidal cells; infundibulum or duct of the frontal sinus uniting with one of the anterior ethmoidal cells; and the orifice of the antrum of Highmore.
11. Inferior turbinated bone, overlapping the inferior meatus, into which the lachrymal canal opens.
12. Spheno palatine foramen transmitting the spheno palatine vessels and nerve.
13. Sphenoidal cells.
14. Dorsum Epphippii.
15. Cerebral surface of the orbital plate of the frontal bone.
16. Frontal sinus.
17. Roof of mouth.

PLATE XX.

THE ORGAN OF HEARING.

The osseous part of the organ of hearing is composed of the external auditory canal, middle ear or tympanum, and internal ear or labyrinth.

The external auditory canal extends from the outer orifice to the membrana tympani. The middle ear, or tympanum, is six-sided, about half-an-inch in length, and a quarter in breadth. Roof corresponds to a portion of the anterior surface of the petrous portion of the temporal bone. Floor is, in position, immediately over the jugular fossa. External wall (see plate) presents:—

1. Membrana tympani.
2. Glasserian fissure in front of the membrana, through which the laxator tympani muscle and small tympanic artery enter, in which also the processus gracilis of the malleus is attached, and parallel with which runs a fine canal for the exit of the chorda tympani nerve.

In contact with the external wall are the ossicula of the ear.

3. Body of the incus.
4. Its short crus.
5. Long crus of the incus.
6. Stapes.
7. Head of malleus.
8. Manubrium of malleus.
9. Processus gracilis of malleus.
10. Processus obtusus of malleus.
11. Mastoid cells.

Internal wall seen in the plate at the depths of the external auditory canal by the removal of the membrana tympani.

1. Aqueductus Fallopi, passage of the portio dura of the seventh nerve: it projects upon the inner wall, but in the plate the surface is removed to expose the open canal.
2. Foramen ovale, orifice into the vestibule: it receives the base of the stapes.
3. The promontory, a prominent surface due to the position of the first turn of the cochlea.
4. Foramen rotundum, a round orifice opening beneath the promontory into the cochlea (its scala tympani).

Posterior wall presents orifices leading into mastoid cells, and a conical elevation termed the pyramid, hollow, and containing the origin of the stapedius muscle.

Anterior wall or extremity of the tympanum, contracts to form two parallel canals, separated from each other by a fine lamina, the processus cochleariformis: the upper canal transmits the tensor tympani muscle and the lower is the Eustachian tube.

Within the tympanum are three small bones, the ossicula.

Malleus:—

1. Head articulates with incus.
2. Neck.
3. Manubrium lies between the layers of the membrana tympani.

4. Processus gracilis, attached within the Glasserian fissure.
5. Processus brevis, extends upwards and outwards, and receives the insertion of the tensor tympani.

Incus:—

1. Facet upon body for articulation with the head of the malleus.
2. Short crus, attached to the mastoid cells.
3. Long crus, parallel with but behind the manubrium: it articulates with the stapes, a small bone, the
4. Os orbiculare, intervening.

Stapes:—

1. Head articulates with os orbiculare.
2. Base, flat and oval, fits into the foramen ovale.
3. Anterior crus, the shorter.
4. Posterior or long crus.

LABYRINTH.

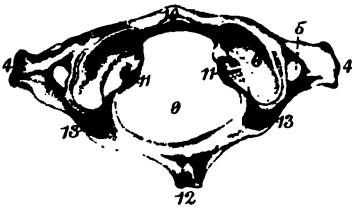
1. Vestibule, composed of two fossae, one at the anterior and inferior part. The upper is called fossa hemi elliptica, and the lower fossa hemi spherica. Posterior wall of vestibule receives the five orifices of the semicircular canals. On the inner wall at the lower part are the orifices for the filaments of the portio mollis of the seventh nerve, and also the orifice of a canal, the aqueductus vestibuli. On outer wall is fenestra ovalis, leading into tympanum. In anterior wall, at lower part, is the orifice leading to scala vestibuli of the cochlea.
2. Semicircular canals, two vertical and one horizontal. Each is dilated at one extremity, the ampulla, and the two vertical unite together at their non-ampullary extremities, so that only five orifices open into the vestibule.
3. Cochlea is a tube making two and a-half turns around a central axis, (1) the modiolus. The tube is divided into two smaller tubes, termed scala, by a thin plate, the (2) lamina spiralis. The two scalae unite at the apex of the cochlea, which is termed the (3) cupola, but at the base they open one into the vestibule, the scala vestibuli, and the other into the tympanum, the scala tympani. In the scala tympani, near its entrance into the tympanum, is a small orifice, the aqueductus cochleae.
4. Meatus auditorius internus, situated near the base of the cochlea.
5. Aqueductus vestibuli.

DIAGRAM OF COCHLEA.

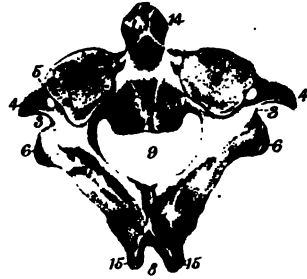
1. Modiolus.
2. Lamina spiralis.
3. Cupola.

THE VERTEBRÆ.

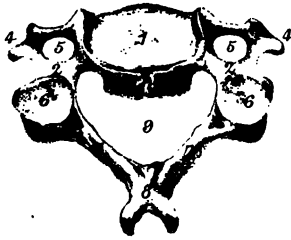
ATLAS



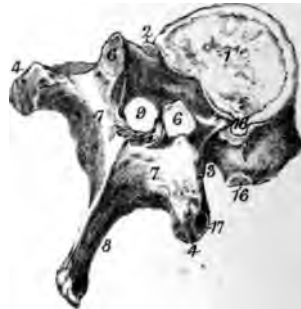AXIS.



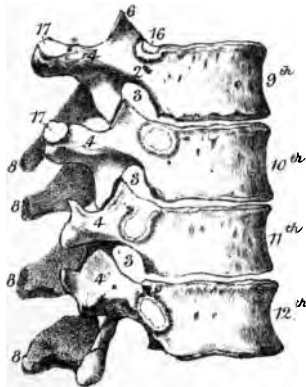
CERVICAL



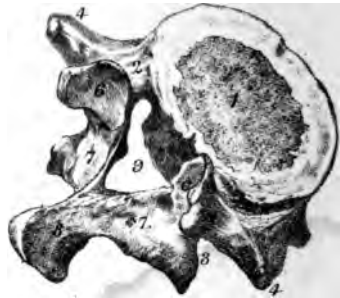DORSAL



LOWER DORSAL



5TH LUMBAR



Where a figure is repeated, a line drawn from one to the other denotes the extent of the part described. O., origin. I., insertion.

PLATE I.

THE VERTEBRÆ.

- | | |
|---|--|
| 1. Body. | 11. Rough depressions for the attachment of the transverse ligament of the atlas. |
| 2. Pedicles. | 12. Rudimentary spine of the atlas, and origin of the two recti capitis postici minores. |
| 3. Vertebral notches through which the spinal nerves leave the canal. | 13. Groove traversed by the vertebral artery and first cervical nerve. |
| 4. Transverse processes: those of the atlas give origin to superior oblique, and insertion to inferior oblique muscles. | 14. Odontoid process. |
| 5. Foramen for the vertebral artery. | 15. O. Inferior oblique, and rectus capitis posticus major. |
| 6. Articular process. | 16. Half facets upon the body of the dorsal vertebræ for articulation with the heads of the ribs. |
| 7. Laminae. | 17. Facets upon the transverse processes of the dorsal vertebræ for articulation with the tubercles of the ribs. |
| 8. Spine. | |
| 9. Spinal foramen. | |
| 10. Anterior arch of atlas. | |

PLATE II.

THE THORAX.

The thorax, a conical space bounded in the median line anteriorly by the sternum, in the median line posteriorly by the bodies of the dorsal vertebræ, laterally by the ribs and their cartilages.

The upper or cervical aperture is bounded by the first dorsal vertebra, the first rib and its cartilage, and the upper border of the manubrium.

The lower or abdominal aperture, much the larger, is bounded by the xyphoid cartilage, the 7th, 8th, 9th, 10th, and the extremities of the 11th and 12th costal cartilages, the lower margin of the last rib, and the 12th dorsal vertebra.

THE RIBS.

1. Head presenting two facets for articulation with two dorsal vertebræ: the ridge separating the facets attaches an interarticular ligament.
2. Neck of the rib: it attaches the anterior costo transverse ligament by its superior margin, and by its posterior surface the middle costo transverse ligament.
3. Tubercle of the rib, articulates by a facet with the transverse process of the lower of the two vertebræ with which it is connected, and by a rough marking gives attachment to the posterior costo transverse ligament.
4. Angle of the rib, between which and the tubercle parts of the erector spinæ take both origin and insertion.
5. Groove of the rib, the two margins of which attach the external and the internal intercostal muscles.
6. Superior border, attaches both external and internal intercostals.
7. Concavity for the reception of the costal extremity of the costal cartilage.

FIRST RIB.

1. Head with one facet only.
2. Neck, does not attach an anterior costo transverse ligament.
3. Tubercle.
4. **O.** Scalenus medius, from a rough line or groove upon the posterior third of the upper surface.
5. Tubercle, and rough line extending from it forwards and outwards, for

the origin of the scalenus anticus muscle.

6. Groove running forwards and outwards behind the scalenus anticus muscle for the subclavian artery.
7. **O.** Subclavius muscle from the upper surface of the rib at its junction with the costal cartilage.
8. Articulation with first costal cartilage.

THE PELVIS.

1. Sacrum.
 2. Ala of ilium, and **O.** internal iliac muscle.
 3. Body of fifth lumbar vertebra.
- The brim of the true pelvis, or separation of the false pelvis is formed by:
4. Horizontal ramus of pubes,
 5. Ilio pectineal eminence,
 6. Ilio pectineal line,
 7. Sacro iliac synchondrosis.

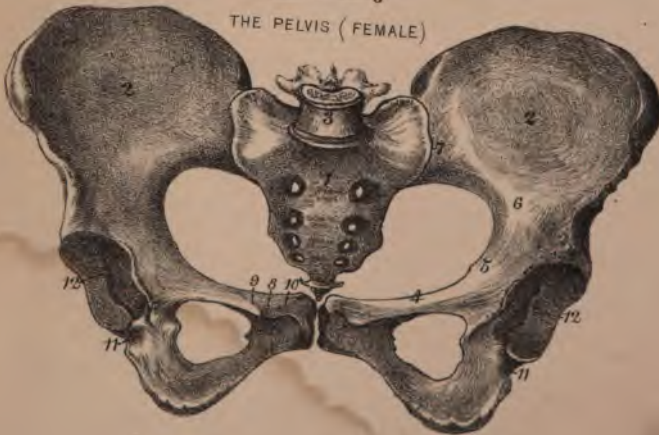
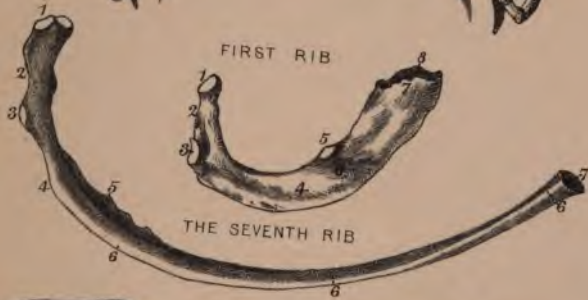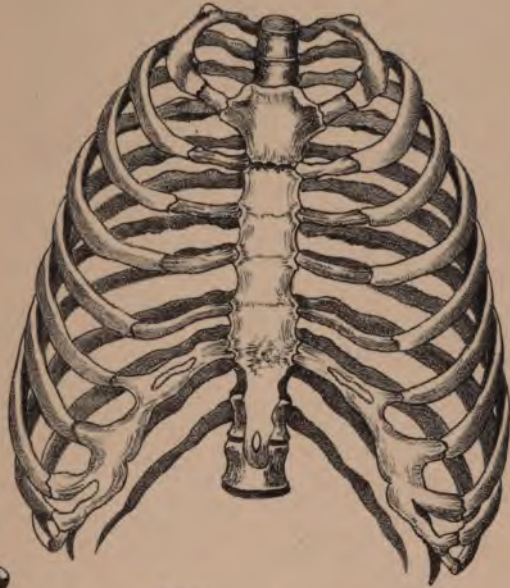
The superior aperture of the true pelvis in the male is larger from before backwards than from side to side, but the reverse in the female, and its plane is such that its axis would be in a line drawn from the umbilicus to the tip of the coccyx.

The inferior aperture of the true pelvis is very irregular, owing to the greater and lesser sciatic notches, and to the downward projection of the coccyx, but it is rendered more even in outline, and smaller in size, by the greater and lesser sacro sciatic ligaments which extend from the sides of the sacrum and coccyx to the tuberosity and to the spine of the ischium. Its plane is such that its axis lies in a line drawn from the promontory of the sacrum through a point midway between the tuberosities of the ischia.

Differences of the female pelvis. More delicately formed; of larger dimensions, particularly from side to side; alæ of ilia more shallow but extended in width; brim oval and larger from side to side than from before backwards; pubic arch larger, broader, smooth and shelving on its posterior aspect, rounded at the symphysis pubis; obturator foramen triangular; sacrum shorter, broader, more curved; coccyx more movable; cavity not so deep.

8. Spine of pubes.
9. Line for the attachment of Gimbernat's ligament.
10. Crest of pubes.
11. Groove for the tendon of the obturator externus muscle.
12. Acetabulum.

THE THORAX



1

1

1

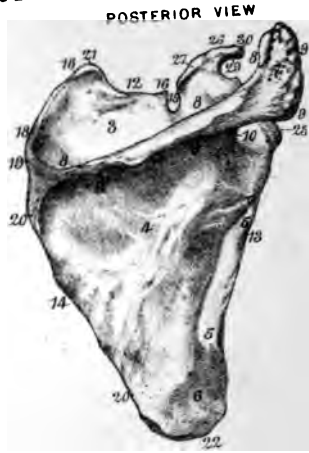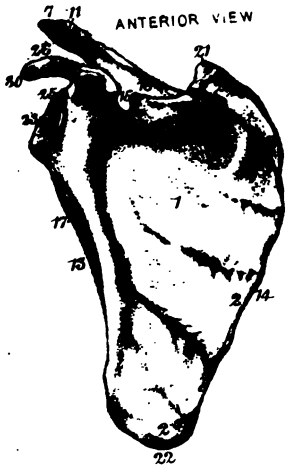1

1

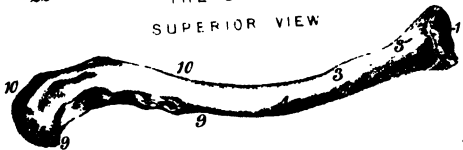
1



THE SCAPULA



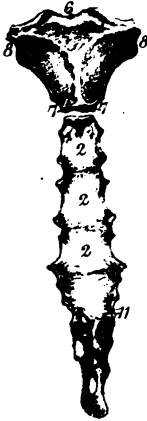
THE CLAVICLE
SUPERIOR VIEW



INFERIOR VIEW



ANTERIOR VIEW



POSTERIOR VIEW



THE STERNUM

PLATE IV.

THE HUMERUS.

1. **H**ead.
2. **A**natomical neck.
3. **E**xternal tuberosity, and **I.** supra-spinous, infraspinous, and **teres minor**.
- 3'. **P**osterior part of external tuberosity, and **I.** **teres minor**.
4. **I**nternal tuberosity and **I.** subscapularis.
5. **B**icipital groove transmitting long head of biceps and articular artery: its external border **I.** pectoralis major, and its internal border **I.** **teres major**, and **latissimus dorsi**.
6. **S**urgical neck.
7. **O.** **B**rachialis anticus.
8. **I**nternal condyloid ridge.
9. **E**xternal condyloid ridge. **O.** supinator radii longus, and extensor carpi radialis longior.
10. **I.** Coraco brachialis.
11. **I.** Deltoid.
12. **O.** Mass of triceps.
13. **O.** External head of triceps as high as **I.** **teres major**.
14. **O.** Internal head of triceps as high as **I.** **teres major**.
15. **M**usculo spiral groove for same nerve.
16. **I**nternal condyle. **O.** pronator radii teres; flexor carpi radialis; palmaris longus; flexor sublimis digitorum; flexor carpi ulnaris.
17. **E**xternal condyle. **O.** extensor carpi radialis brevis; extensor communis digitorum; extensor minimi digiti; extensor carpi ulnaris and anconeus.
18. **C**apitellum articulates with radius.
19. **T**rochlear surface articulates with ulna.
20. **C**oronoid fossa.
21. **F**ossa for head of radius.
22. **O**lecranon fossa.

RADIUS.

1. **H**ead.
2. **N**eck, plays within the annular ligament.
3. **T**uberosity. **I.** biceps.
4. **I**nternal border for interosseous membrane.
5. **S**igmoid cavity of radius, articulates with lower extremity of ulna.
6. **A**nterior border.
7. **O**blique line of the radius. **I.** supinator radii brevis. **O.** flexor sublimis digitorum.
8. **I.** Pronator quadratus into lower fifth of the radius.

9. **O.** Flexor longus pollicis from $\frac{3}{4}$ only of the depression below the oblique line.
10. **I.** Supinator brevis.
11. **O.** Extensor ossis metacarpi pollicis.
12. **O.** Extensor primi internodii pollicis.
13. **I.** Pronator radii teres.
14. **A**rticular facet for scaphoid and semi-lunar bones.
15. **S**tyloid process, apex attaches external lateral ligament of wrist.
16. **I.** Supinator radii longus.
17. **G**roove for extensor ossis metacarpi pollicis and extensor primi internodii pollicis.
18. **G**roove for extensor secundi internodii pollicis.
19. **G**roove for extensor communis digitorum, and extensor indicis.
20. **G**roove for extensor carpi radialis longior and brevis.

ULNA.

1. **O**lecranon process.
2. **C**oronoid process.
3. **G**reat sigmoid cavity.
4. **L**esser sigmoid cavity.
5. **I.** Triceps upon upper surface of olecranon process.
6. **I.** Brachialis anticus upon coronoid process.
7. **T**ubercle for oblique ligament.
8. **O.** Second head of pronator radii teres and flexor sublimis digitorum.
9. **I**nterosseous or external border.
10. **O.** Flexor profundus digitorum, from anterior and internal surface of ulna.
11. **O.** Pronator quadratus.
12. **P**osterior border: it attaches an aponeurosis common to flexor prof. dig.; flexor carpi ulnaris, and extensor carpi ulnaris.
13. **O.** Supinator brevis, fossa below lesser sigmoid cavity.
14. **I.** Anconeus, triangle above oblique line.
15. **O.** Extensor ossis metacarpi pollicis.
16. **O.** Extensor primi internodii pollicis.
17. **O.** Extensor secundi internodii pollicis.
18. **O.** Extensor indicis.
19. **A**rticular surface of inferior extremity.
20. **S**tyloid process, apex attaches internal lateral ligament.
21. **G**roove for the tendon of extensor carpi ulnaris.

PLATE III.

THE STERNUM.

1. **O.** Sternal portion of sterno mastoid, by a rounded tendon.
2. **O.** Pectoralis major.
3. **O.** Sterno hyoid.
4. **O.** Sterno thyroid.
5. Facet for articulation with the clavicle.
6. Interclavicular notch.
7. Half facet for second costal cartilage.
8. Rough margin for attachment of the first rib.
9. **O.** Triangularis sterni.
10. **O.** Diaphragm.
11. Position at which the ensiform or xyphoid cartilage is attached to the gladiolus.

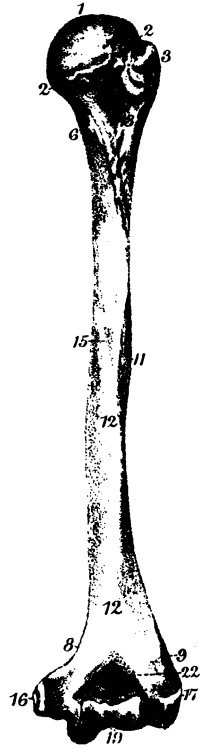

THE CLAVICLE.

1. Facet for articulation with sternum.
2. Oval facet for articulation with the acromion process of the scapula.
3. **O.** Clavicular portion of sternocleido mastoid, nearly two inches in length.
4. **O.** Clavicular portion of pectoralis major, from sternal half of anterior aspect.
5. Rhomboid depression for costo clavicular ligament.
6. Subclavian groove, in the depths of which the subclavius muscle is inserted, and to the borders the costo coracoid ligament is attached: in it also is usually the nutrient foramen.
7. Tubercle which attaches conoid portion of coraco clavicular ligament.
8. Line which attaches trapezoid portion of coraco clavicular ligament.
9. **O.** Deltoid from the anterior border of the outer third of the clavicle.
10. **I.** Trapezius, posterior border of the outer third of the clavicle.

THE SCAPULA.

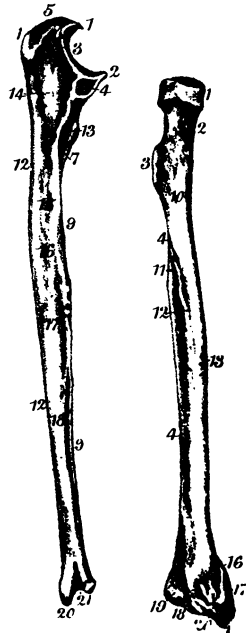
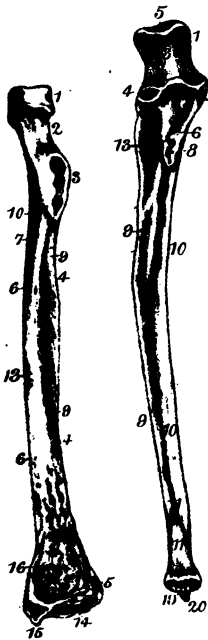
1. Anterior surface, or venter and **O.** subscapularis.

2. **I.** Serratus magnus into the anterior aspect of the posterior margin.
3. Supraspinous fossa and **O.** supraspinous muscle.
4. Infraspinous fossa and **O.** infraspinous muscle.
5. **O.** Teres minor from dorsal aspect of the anterior border.
6. **O.** Teres major from dorsal aspect of lower angle.
7. Acromion process gives **O.** to deltoid by lower border, **I.** to trapezius by upper border.
8. Superior margin of spine and **I.** trapezius.
9. Inferior margin of spine and **O.** deltoid.
10. External margin of spine, and boundary of the neck.
11. Facet for articulation with clavicle.
12. Superior border of the scapula.
13. External or axillary border.
14. Internal or vertebral border, base.
15. Suprascapular notch, transmits suprascapular nerve.
16. **O.** Omo hyoid muscle.
17. **O.** Long head of triceps, from fossa one inch and a half in length upon the anterior border.
18. **I.** Levator anguli scapulae.
19. **I.** Rhomboideus minor.
20. **I.** Rhomboideus major.
21. Superior angle of the scapula.
22. Inferior angle: it often attaches fibres of latissimus dorsi.
23. External angle or head of the scapula.
24. The glenoid fossa, pyriform in shape with the apex upwards.
25. **O.** Long head of biceps from the glenoid ligament at the apex of the glenoid fossa.
26. The coracoid process.
27. Coraco clavicular ligaments, conoid and trapezoid.
28. **I.** Pectoralis minor into the anterior border of coracoid process.
29. Coraco acromial ligament, attached by its base to the posterior margin of the coracoid process.
30. **O.** Coraco brachialis, and short head of biceps from the apex of the coracoid process.



HUMERUS

POSTERIOR VIEW.



RADIUS & ULNA

1




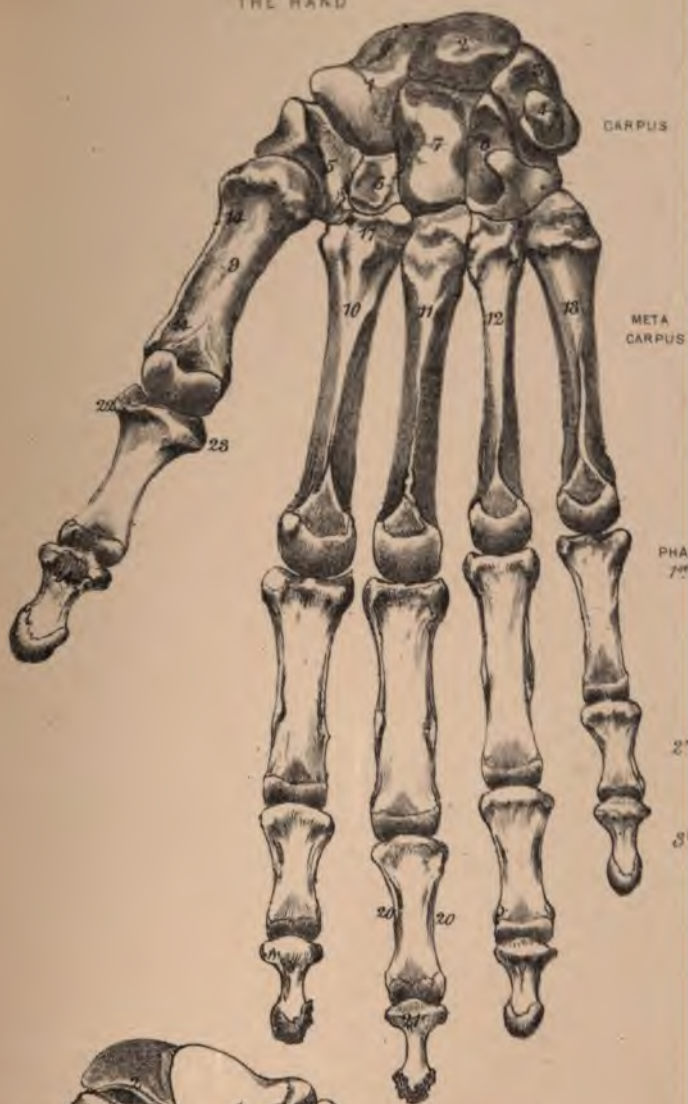
PLATE VI.

THE HAND.

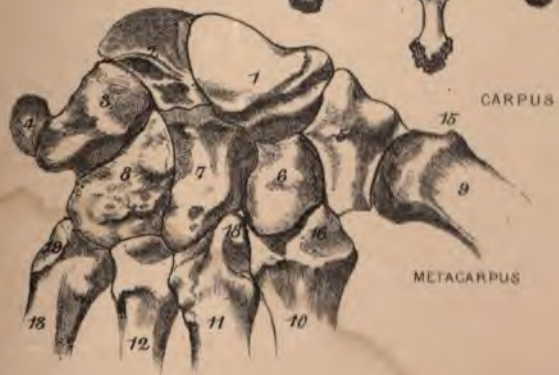1. Scaphoid.
 2. Semilunar.
 3. Cuneiform.
 4. Pisiform.
 5. Trapezium.
 6. Trapezoid.
 7. Os Magnum.
 8. Unciform.
 9. Metacarpal bone of thumb.
 10. Metacarpal bone of index.
 11. Metacarpal bone of middle finger.
 12. Metacarpal bone of ring finger.
 13. Metacarpal bone of little finger.
 14. **I.** Flexor ossis metacarpi pollicis, or opponens pollicis, into the whole length of the metacarpal bone.
 15. **I.** Extensor ossis metacarpi pollicis, into tubercle upon outer side of the base of the metacarpal bone of the thumb.
 16. **I.** Extensor carpi radialis longior, into posterior aspect of the base of the metacarpal bone of the index finger.
 17. **I.** Flexor carpi radialis, into anterior aspect of the same.
 18. **I.** Extensor carpi radialis brevior, into tubercle upon the posterior aspect of the base of the metacarpal bone of the middle finger.
 19. **I.** Extensor carpi ulnaris, into the posterior aspect of the base of the metacarpal bone of the little finger.
 20. **I.** Flexor sublimis digitorum, into both sides of the middle phalanx of the fingers.
 21. **I.** Flexor profundus digitorum, into the anterior aspect of the base of the terminal phalanx of the fingers.
 22. **I.** Abductor pollicis and outer head of flexor brevis pollicis, into outer side of the first phalanx of the thumb.
 23. **I.** Adductor pollicis and inner head of flexor brevis pollicis, into inner side of the same.
 24. **I.** Flexor longus pollicis, into anterior surface of the base of the terminal phalanx of the thumb.
- Interosseous muscles arise from the adjacent surfaces of the metacarpal bones.

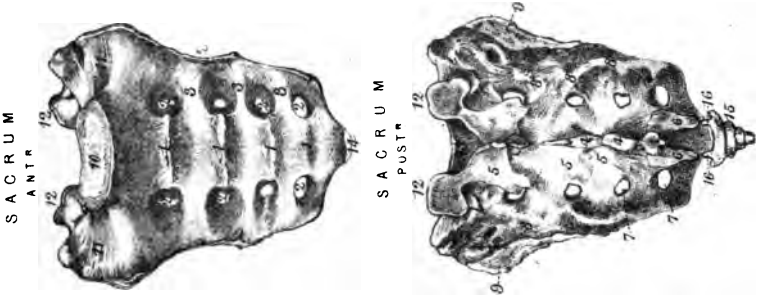
THE HAND

ANTERIOR VIEW.

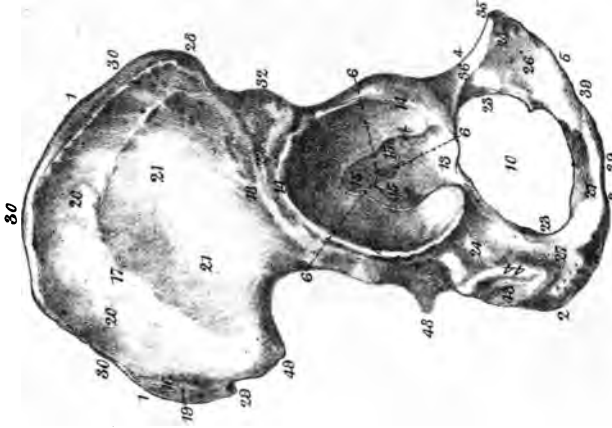


POSTERIOR VIEW.





OS INNOMINATUM.
EXTERNAL VIEW.



INTERNAL VIEW.

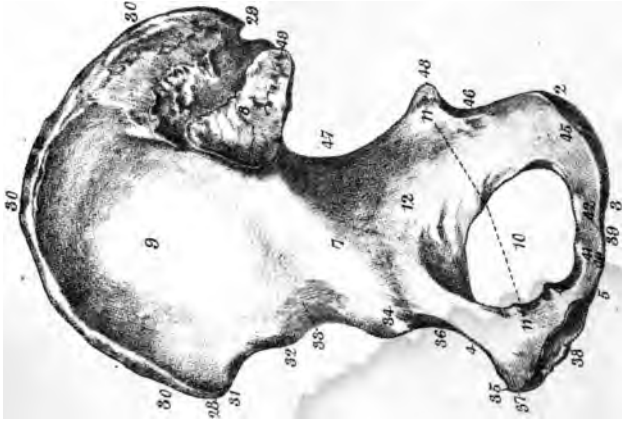


PLATE VII.

THE SACRUM.

1. Transverse lines, original separation of sacral vertebrae.
2. Anterior sacral foramina, for anterior sacral nerves.
3. *O.* Pyramiformis from three central vertebrae.
4. Rudimentary spinous processes.
5. Laminae and *O.* erector spinae.
6. Cornua of the sacrum.
7. Posterior sacral foramina posterior
sacral nerves.
8. Incorporated transverse processes, and *O.* gluteus maximus, and sacro sciatic ligaments.
9. Lateral surface, part rough for sacro iliac ligament.
10. Body of first sacral vertebra.
11. Ala of sacrum.
12. Superior articular processes.
13. Sacro spinal canal.
14. Apex of sacrum.
15. Coccyx, margin attaches sciatic ligaments, and *O.* gluteus maximus. *I.* coccygeus; apex *O.* sphincter ani.
16. Cornua of the coccyx.

OS INNOMINATUM.

1. Ala of ilium.
2. Tuberosity of ischium.
3. Ascending ramus of ischium.
4. Horizontal ramus of pubes.
5. Descending ramus of pubes.
6. Junction of the three bones in the acetabulum.
7. Ilio pectineal line.
8. Auricular surface for articulation with sacrum, and part rough for sacro iliac ligaments.
9. *O.* Iliacus muscle from whole of iliac fossa.
10. Obturator foramen transmits obturator vessels and nerve.
11. *O.* Levator ani from fascia stretched from pubes to spine of ischium.
12. *O.* Obturator internus, from the circumference of the foramen and surface behind it.
13. Vascular aperture to joint.
14. Cotyloid ligament around circumference of acetabulum, and continued across the notch by the transverse ligament.
15. Ligamentum teres.
The capsular ligament is attached outside the cotyloid.
16. Superior curved line.
17. Middle curved line.
18. Inferior curved line.
19. *O.* Gluteus maximus.
20. *O.* Gluteus medius, from whole of surface between superior and middle curved lines.
21. Gluteus minimus, from surface between middle and inferior lines.
22. *O.* External head of rectus femoris, between inferior line and acetabulum.
23. *O.* Obturator externus, from inner half of obturator foramen.
24. Groove for tendon of obturator externus.
Below this groove, extending on to the tuberosity, the gemellus inferior arises.
25. *O.* Adductor longus by a round tendon.
26. *O.* Adductor brevis.
27. *O.* Adductor magnus.
28. Anterior superior spine (Poupart's ligament).
29. Posterior superior spine.
30. Crest of ilium, extending between the anterior superior and the posterior superior spines, divided into three lines or lips, of which the external: *O.* tensor fasciae femoris, anterior inch. *I.* obliquus externus anterior $\frac{1}{2}$. *O.* latissimus dorsi posterior $\frac{1}{2}$. Middle lip. *O.* obliquus internus at anterior $\frac{1}{2}$. *O.* erector spinae posterior $\frac{1}{2}$. Internal lip. *O.* transversalis abdominis, from anterior $\frac{1}{2}$. *O.* quadratus lumborum, posterior $\frac{1}{2}$.
31. *O.* Sartorius, from one inch of anterior border.
32. Anterior inferior spine, *O.* internal head of rectus femoris, and ilio femoral ligament.
33. Groove for psoas and iliacus.
34. Ilio pectineal eminence. *I.* psoas parvus.
35. Spine of pubes (Poupart's ligament), and extending one inch outwards. *I.* Gimbernat's ligament.
36. *O.* Pectineus from ridge, and depression in front.
37. Crest of pubes. *I.* tendon of external oblique, internal oblique, and transversalis. *O.* pyramidalis, and rectus abdominis.
38. Surface for articulation with fellow.
39. *O.* Gracilis, from two inches of the margin.
40. Crus penis, attached to about an inch and a-half of the pubic arch, and *O.* erector penis along its outer margin and below it.
41. *O.* Elevator and constrictor urethrae.
42. *O.* Transversus perineci.
43. *O.* Hamstrings from tuberosity of ischium (semimembranosus, long head of biceps, and semitendinosus).
44. *O.* Quadratus femoris, from outer margin of tuberosity of ischium.
45. Great sacro sciatic ligament attached to lip on internal margin of tuberosity.
46. Lesser sciatic notch, transmitting internal pudic vessels and nerve into the perineum, and obturator internus out of the pelvis.
47. Great sciatic notch transmitting out of the pelvis gluteal vessels and nerve, pyriformis muscle, sciatic and pudic vessels and nerves.
48. Spine of ischium, attaches lesser sacro sciatic ligament, and on its outer surface *O.* gemellus superior, on its inner *O.* levator ani and coccygeus.
49. Posterior inferior spine of the ilium.

PLATE VIII.

THE FEMUR.

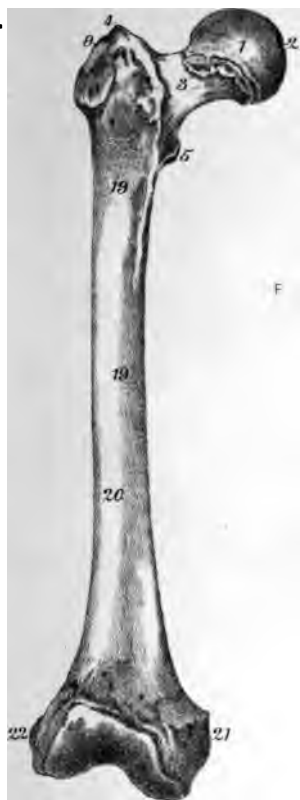
1. Head.
2. Depression for ligamentum teres.
3. Neck.
4. Trochanter major.
5. Trochanter minor. *I. Psoas* and *illicus*.
6. *I. Gluteus minimus* on the fore part of the great trochanter.
7. *I. Piriformis*, gemellus superior, obturator internus and gemellus inferior upon upper margin of great trochanter.
8. Digital fossa. *I. obturator externus*.
9. *I. Gluteus medius* into oblique line on outer surface of great trochanter.
10. *O. Vastus externus* from base of great trochanter, line leading from great trochanter to *linea aspera*, outer lip of *linea aspera*, and a-half the line from *linea aspera* to outer condyle.
11. *O. Vastus internus* from internal surface of femur, internal lip of *linea aspera*, lines leading from *linea aspera* upwards to small trochanter downwards to internal condyle.
12. *I. Adductor magnus* into middle lip of *linea aspera*, line leading from *linea aspera* to great trochanter, part of line from *linea aspera* to inner condyle, and by a tendon into a tubercle upon the inner condyle.
13. *I. Quadratus femoris* into *linea quadrati*, or line extending upon posterior margin of great trochanter.
14. *I. Gluteus maximus* into three inches of line from great trochanter to *linea aspera*, between the adductor magnus and *vastus externus*.
15. *O. Short head of biceps* from *linea aspera* and line to outer condyle between adductor magnus and *vastus externus*.
16. *I. Adductor longus* into *linea aspera*, middle third of the bone between adductor magnus and *vastus internus*.
17. *I. Adductor brevis* into line from lesser trochanter to *linea aspera*.
18. *I. Pectineus* in same line in front of adductor brevis.
19. *O. Crureus* from front of femur as high as intertrochanteric line, connected with *vastus internus*.
20. *O. Subcrureus* from front of femur, lower third.
21. Internal condyle, attaches internal lateral ligament.
22. External condyle, attaches external lateral ligament.
23. *O. Popliteus* from fossa on outer surface of external condyle.
24. Anterior crucial ligament into external condyle.
25. Posterior crucial ligament into internal condyle.
26. *O* Outer head of *gastrocnemius* and the *plantaris* from a fossa above external condyle, the latter being external.
27. *O* Inner head of *gastrocnemius* from fossa over inner condyle.
2. Spine of tibia with fossa in front and behind for anterior and posterior crucial ligaments.
3. Internal tuberosity.
4. External tuberosity.
5. *I. Semimembranosus* into posterior part of internal tuberosity.
6. Facet for articulation with fibula.
7. Groove for tendon of *popliteus*.
8. Tubercle of tibia, attaches ligamentum patellae.
9. Anterior border.
10. Internal border.
11. External border, attaches interosseous membrane.
12. Fossa for attachment of the lower extremity of the fibula.
13. Internal surface, subcutaneous.
14. *I. Sartorius*, gracilis and *semitendinosus*.
15. External surface. *O. Tibialis anticus*, from upper $\frac{3}{4}$.
16. Oblique line of tibia. *O. Soleus*.
17. Triangular surface above oblique line. *I. Popliteus*.
18. *O. Flexor longus digitorum*, from about the central half of posterior surface.
19. *O. Tibialis posticus*, from outer margin of posterior surface.
20. Internal malleolus.
21. Surface for articulation, with astragalus.
22. Anterior ligament of ankle-joint.
23. Internal lateral ligament of ankle
24. Groove for tendons of *tibialis posticus* and *flexor communis digitorum*.

THE FIBULA.

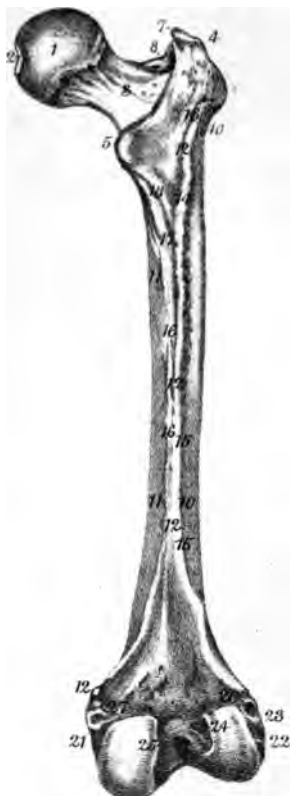
1. Facet for articulation with tibia.
2. Styloid process: apex attaches short external lateral ligament.
3. *I. Biceps*.
4. Anterior internal or interosseous line.
5. Anterior external border or line.
6. Posterior internal line.
7. Posterior external line.
8. Rough surface for ligamentous attachment with tibia.
9. *O. Extensor longus digitorum*, from head and upper $\frac{1}{4}$ of anterior surface.
10. *O. Peroneus tertius*, from lower fourth of anterior surface, being continuous with previous muscle.
11. *O. Flexor proprius pollicis*, from middle $\frac{3}{4}$ of anterior surface internal to *extensor longus digitorum*.
12. *O. Peroneus longus* and *brevis*, from outer surface of fibula.
13. *O. Soleus*, from head and upper fourth of posterior surface.
14. *O. Flexor longus pollicis*, from the lower $\frac{3}{4}$ of posterior surface.
15. *O. Tibialis posticus*, from the space between the interosseous line and the posterior internal line, which may be called the internal surface of the fibula.
16. Surface for articulation, with astragalus.
17. Groove for tendons of the *peroneus longus* and *brevis*.
18. Attachment of middle fasciculus of external lateral ligament.
19. Subcutaneous surface or outer ankle.

THE TIBIA.

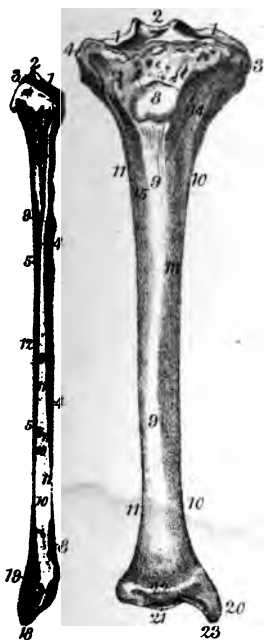
1. Articular surfaces for condyles of femur; circumferences attach the semilunar cartilages.



F E M U R



P O S T E R I O R V I E W .



T I B I A & F I B U L A

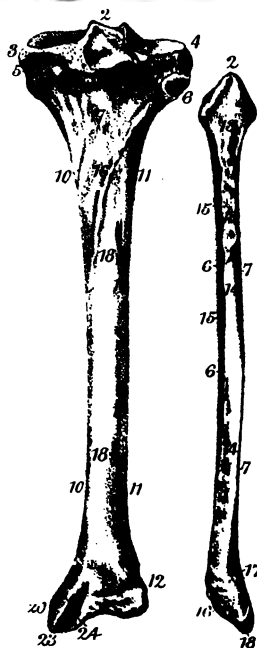
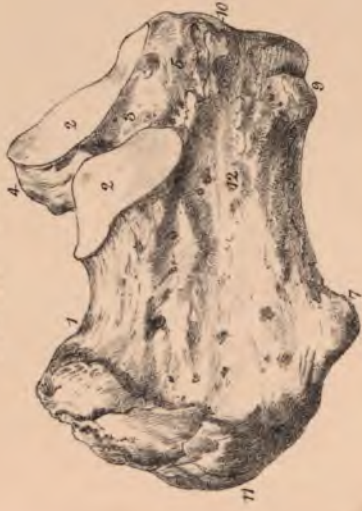
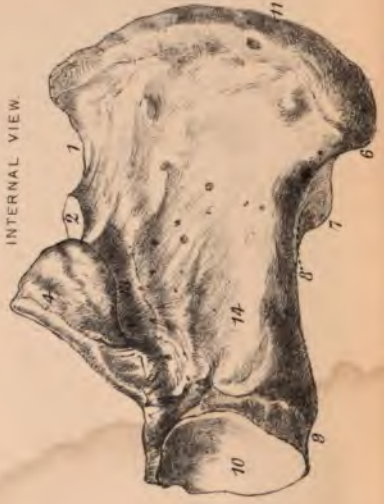
Plate IX

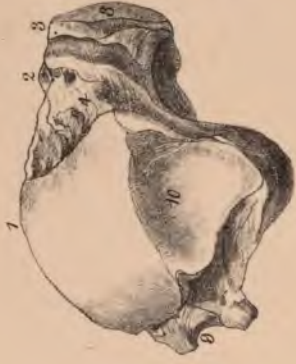OS CALCIS
EXTERNAL VIEW



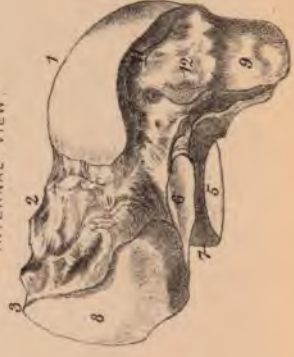INTERNAL VIEW



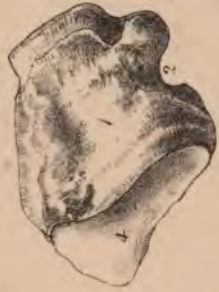ASTRACALUS
EXTERNAL VIEW



INTERNAL VIEW



CUBOID
SUPERIOR VIEW



INFERIOR VIEW

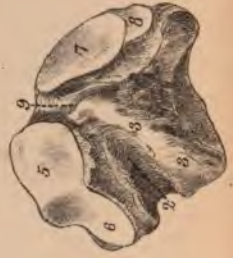

PLATE IX.

THE TARSUS.

OS CALCIS.

1. **S**pace occupied by fat, &c.
2. **F**acets for articulation with astragalus.
3. **G**roove for calcaneo astragaloid ligament.
4. **S**ustentaculum tali grooved on its under surface by the flexor longus pollicis.
5. **O**. Extensor brevis digitorum from the upper and outer surface of the anterior extremity of the os calcis.
6. **I**nternal tubercle. **O**. Abductor pollicis and flexor brevis digitorum.
7. **E**xternal tubercle. **O**. Abductor minimi digiti.
8. **A**ttachment of long plantar or long calcaneo cuboid ligament to under surface of the os calcis near the tubercles.
9. **S**hort plantar or short calcaneo cuboid ligament from tubercle at the anterior extremity of the under surface.
10. **A**nterior surface of os calcis, articulates with the cuboid bone.
11. **I**. Tendo Achillis into lower part of the posterior surface.
12. **A**ttachment of the middle fasciculus of the external lateral ligament of the ankle. In front of this there are often two grooves for the peronei muscles.
13. **G**roove upon under surface of the sustentaculum tali for flexor longus pollicis.
14. **O**. Flexor accessorius from the inner surface of the os calcis.

ASTRAGALUS.

1. **B**ody.
2. **N**eck.
3. **H**ead.
4. **R**ough depression for the anterior fasciculus of the external lateral ligament, and also the anterior ligament of the ankle.
5. **P**osterior facet, articulates with os calcis.
6. **A**nterior facet, articulates with os calcis.
7. **G**roove for astragalo calcanean ligament.
8. **A**nterior surface of the head, for articulation with the scaphoid bone.
9. **G**roove for the tendon of the flexor longus pollicis.
10. **E**xternal surface, articulates chiefly with the outer malleolus.
11. **F**acet for articulation with the internal malleolus, generally very small.
12. **A**ttachment of internal lateral ligament.

CUBOID.

1. **D**orsal surface.
2. **G**roove for the tendon of the peroneus longus.
3. **P**osterior ridge of the peroneal groove and attachment of the long plantar ligament.
4. **P**osterior surface, articulates with the os calcis.
5. **A**rticular facet on anterior surface for the fourth metatarsal bone.
6. **A**rticular facet on anterior surface for fifth metatarsal bone.
7. **A**rticular facet near the centre of the internal surface for external cuneiform bone.
8. **A**rticular facet upon the posterior part of the internal surface for the scaphoid bone.
9. **R**ough marking for the interosseous ligament between the cuboid and the external cuneiform bone.

PLATE X.

THE TARSUS.

SCAPHOID.

1. Posterior surface, concave for articulation with astragalus.
2. Portion of the anterior surface for articulation with the internal cuneiform bone.
3. Portion for middle cuneiform bone.
4. Portion for external cuneiform bone.
5. *I. Tibialis posticus* into the tuberosity of the scaphoid bone.
6. Small facet for articulation with the cuboid bone.
7. Superior or dorsal surface.
8. Inferior or plantar surface.

INTERNAL CUNEIFORM.

1. Posterior surface, articulates with scaphoid bone.
2. Anterior surface, kidney-shaped, articulates with the metatarsal bone of the great toe.
3. Facet of angular form upon outer surface for middle cuneiform bone.
4. Small facet upon the anterior part of the external surface for articulation with the side of the second metatarsal bone.
5. Smooth marking over which the tendon of the *tibialis anticus* and often a sesamoid bone play.
6. Plantar surface and the base of the wedge which the bone represents.
I. Tibialis anticus.

MIDDLE CUNEIFORM

(is the smallest of the three).

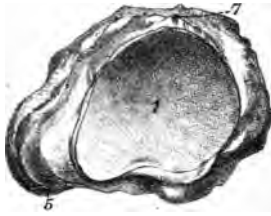
1. Posterior surface, articulates with the scaphoid bone.
2. Anterior surface, articulates with the second metatarsal bone.
3. Angular facet, the angle being at the upper and posterior corner, upon the inner surface of the bone, for articulation with the internal cuneiform bone.
4. Facet upon outer surface for articulation with the external cuneiform bone.

EXTERNAL CUNEIFORM.

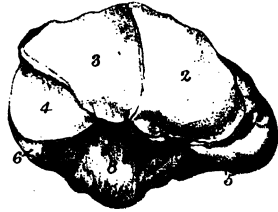1. Posterior surface for articulation with the scaphoid bone.
2. Anterior surface for third metatarsal bone.
3. Facet upon the posterior part of inner surface for the middle cuneiform bone.
4. Small facet upon the anterior part of the inner surface for articulation with the side of the second metatarsal bone.
5. Facet upon the posterior part of outer surface for articulation with the cuboid bone.
6. Small facet upon the anterior part of the external surface for articulation with the side of the fourth metatarsal bone.

SCAPHOID BONE

POSTERIOR VIEW.

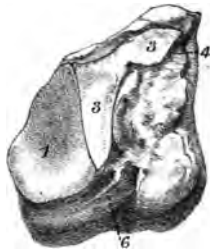


ANTERIOR VIEW

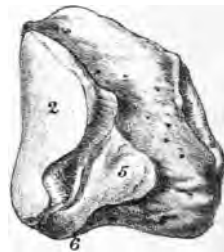

INTERNAL CUNEIFORM

EXTERNAL VIEW

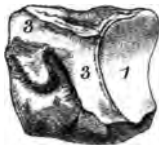

INTERNAL VIEW

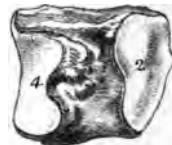

MIDDLE CUNEIFORM.

INTERNAL VIEW.

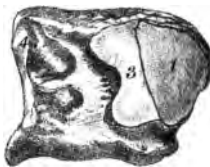


EXTERNAL VIEW

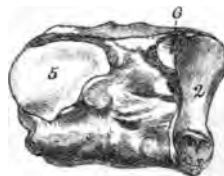

EXTERNAL CUNEIFORM

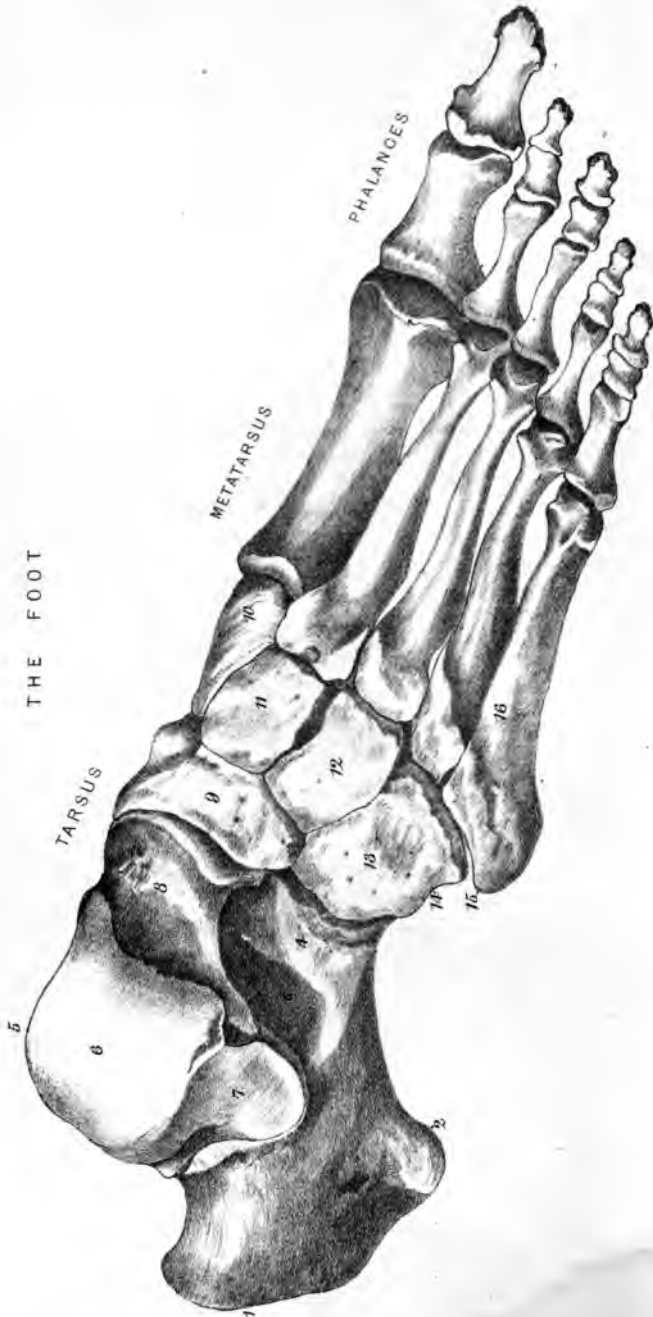INTERNAL VIEW



EXTERNAL VIEW



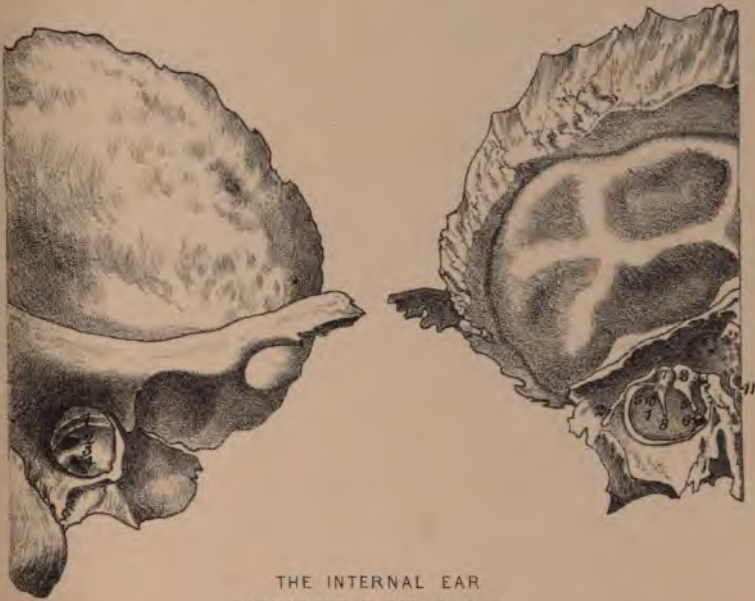THE FOOT



THE ORGAN OF HEARING.

INTERNAL WALL OF THE TYMPANUM

EXTERNAL WALL OF THE TYMPANUM



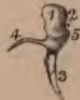THE INTERNAL EAR
COMPONENT PARTS IN SITU



COCHLEA



MALLEUS



INCUS



STAPES



